

accurate histopathology. Our aim was to explore whether CLE can be used for detection and characterization of ACF. In a prospective pilot-study, chromoendoscopy-guided CLE was performed to detect and characterize ACF in a group of patients at high-risk for colorectal cancer (CRC) and in a control group. **Methods:** Thirty-three patients who underwent CLE using the Pentax EC3870CIFK colonoscope were included in this study. Fourteen patients had Lynch syndrome (LS), 9 had familial CRC and 10 were control subjects with normal endoscopic findings. Optical biopsies from 560 microscopic fields (106 sites) were obtained from the right, the left colon and rectum in a standardized, stepwise fashion. In case of localized colorectal lesions additional optical biopsies were obtained within 10cm from the lesion. ACF were defined as presence of either *morphologic* criteria (presence of ≥ 2 crypts which stain darker than surrounding mucosa; at least 1.5-fold enlarged diameter; elongated, branched lumen), *proliferative* criteria (crypt fission) or a *combination* of both. Four types of ACF were described: type 0 (no abnormalities), type 1 (morphological changes only), type 2 (proliferative changes only), and type 3 (combination). Prevalence data were compared using chi-square test with Fisher's exact test when indicated. **Results:** Patients with LS showed more frequently ACF vs controls at all sites, but mainly in the right colon (11/14 vs 2/10, $p=0.011$) and rectum (14/14 vs 3/10, $p<0.001$). Patients with familial CRC showed more frequently ACF in the rectum vs controls (8/9, vs 3/10, $p=0.02$). No differences were found between this group and controls with regard to right and left-colon. In total, 7 neoplasms were found, of which 4 in the LS-group (3 adenomas and 1 CRC), and 3 adenomas in the familial CRC-group. In all these cases ACF were present within 10 cm from the lesion. Of them 86% were type 3 and 14% were type 1. **Conclusion:** Confocal laser endomicroscopy is a promising technique to detect and characterize ACF in patients at high-risk for CRC. Larger scale, follow-up studies are needed to confirm correlation between CLE and routine histology, as well as potential relevance of ACF during surveillance of these patients.

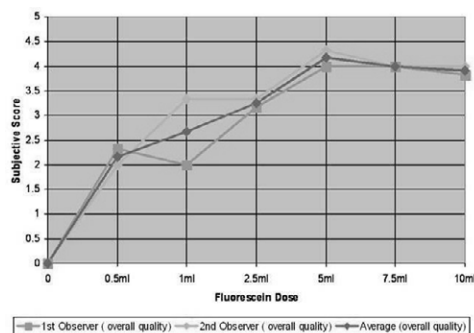
T1219

Determination of the Optimal Fluorescein Dose of Probe-Based Confocal Laser Endomicroscopy in Colonic Imaging

Muhammad W. Shahid, Alexander Meining, Valentin Becker, Aymeric Perchant, Anna M. Buchner, Victoria Gomez, Michael B. Wallace

Background: Probe based confocal laser endomicroscopy (pCLE) is rapidly emerging as highly accurate method for *In Vivo* imaging of gastrointestinal tract. All CLE methods in clinical use rely on IV fluorescein to view blood vessels, and by negative staining of cells and non-vascular structures. To date, no studies have determined optimal dose of IV fluorescein for CLE. **Methods:** In a prospective, IRB-approved phase 1 trial in patients with colorectal neoplasia, we administered a single initial IV fluorescein (AK-Fluor, Akorn Pharmaceutical, Somerset, NJ) dose and then acquired pCLE images using the ultra-high definition probe (UHD, Mauna Kea Technologies) from normal appearing cecum for at least 2 minutes. Video images were rated for subjective quality (1-poor to 5-equivalent to histology) by two experts blinded to dose and quantitative signal to noise ratio (SNR). Doses were escalated in groups of 3 patients including 0.5ml, 1ml, 2.5ml, 5ml, 7.5ml and 10ml of 10% fluorescein. **Results:** 18 patients completed dose escalation study. No complications were observed. A total of 24,892 images were analyzed for quality and SNR. The mean SNR increased steadily from lowest dose (mean SNR12.369) to 7.5ml dose (mean SNR17.1, $p<0.001$ for difference) and decreased with highest dose (10ml, SNR 4.61). The subjective quality of image increased as dose increased from a rating of 1.99 at 0.5ml dose, to 4.04 at the 5ml dose. However, further increase in the dose of fluorescein does not result in any significant improvement in image quality. The pCLE at 5ml dose produced images near histological quality. **Conclusion:** The highest quality and signal to noise images for pCLE imaging are obtained at 5-7.5ml of 10% IV fluorescein. According to basic principals of pharmacology, minimum of two doses i.e., 5ml was considered as the optimal safe dose.

Dose(ml) of 10% Fluorescein	0.5ml	1ml	2.5ml	5ml	7.5ml	10ml
Mean Signal to noise ratio(SNR)	12.37	14.11	15.22	15.57	17.11	14.61



T1220

Endomicroscopic Video Retrieval Approach to Support Diagnostic Differentiation Between Neoplastic and Non-Neoplastic Colonic Polyps

Barbara André, Tom K. Vercauteren, Michael B. Wallace, Nicholas Ayache, Anna M. Buchner

Background: Probe-based confocal laser endomicroscopy (pCLE) enables dynamic imaging of the gastrointestinal epithelium *In Vivo* during ongoing endoscopy and, as of today, relies on the endoscopist for image understanding. The subjective nature of pCLE video semantics suggests the need for a standardized and more automated method for image sequence interpretation. **Aims:** To support the diagnosis of a newly acquired pCLE video, we aim at retrieving from a training database videos that have a similar appearance to the video of

interest and that have been previously diagnosed by expert physicians with confirmed histology. As a model system, we used distinction of adenomatous and hyperplastic colorectal polyps. **Methods:** 68 patients underwent colonoscopy with pCLE for fluorescein-aided imaging of suspicious colonic polyps before their removal. The resulting database is composed of 121 videos (36 non-neoplastic, 85 neoplastic) and 499 edited video sub-sequences (231 non-neoplastic, 268 neoplastic) annotated by clinical experts with a pathological diagnosis. To quantify the relevance of video retrieval, we performed an unbiased classification with leave-one-patient-out cross-validation, based on the voting of the k most similar videos. The Bag-of-Visual-Words method from computer vision extracts local continuous image features and clusters them into a finite number of visual words to build an efficient image signature. In order to retrieve videos and not only isolated images, we revisited this method and analyzed the impact of including spatial overlap between time-related images. We first used the results of a video-mosaicing technique to weight the contribution of each local image region to its visual word. Then, we computed the video signatures with a histogram summation technique, which reduces both retrieval runtime and training memory. **Results:** Video classification results show that our method achieves, when using the votes of the k=9 most similar videos, a sensitivity of 97.7% and a specificity of 86.1% for a resulting accuracy of 94.2%. When compared to using the still images independently, using video data improves the results in a statistically significant manner (McNemar's test: p-value=0.021 when using the votes of the k=3 most similar videos). Moreover, fewer similar videos are necessary to classify the query at a given accuracy, which is clinically relevant for the physician. **Conclusion:** Our method using the results of video-mosaicing for content-based video retrieval appears to be highly accurate for pCLE videos. It may provide the endoscopist with diagnostic decision support and avoid unnecessary polypectomy of non-neoplastic lesions.

T1221

A Novel Endomicroscopically-Guided Polypectomy Snare With Integrated Confocal Probe

Pushpak Taunk, Eladio Rodriguez-Diaz, Satish K. Singh

PURPOSE: With current endoscopic snares, polyps are removed and assessed histopathologically *post-facto* for neoplasia within the resected margins. A "smart" snare system could identify neoplastic tissue to guide resection in real-time. Probe-based confocal laser endomicroscopy (pCLE) permits *In Vivo* fluorescence imaging of mucosal cellular structures via a fiberoptic imaging bundle. The aim of the present study was to use pCLE to design, prototype and test an integrated, image-guided snare tool for colonoscopic polypectomy. **METHODS:** With IRB approval, subjects were recruited from a pool of patients referred for colonoscopy at VA Boston. When polypectomy was indicated, we used a snare electrocautery device prototyped in our bioengineering lab containing a 1 mm diameter "cholangioflex" mini-probe (Cellvizio, Inc.) The tool permitted separation and reprocessing of the optical probe from a single-use snare. The integrated pCLE snare was advanced through the working channel of the colonoscope. Following standard fluorescein injection, the tip of the integrated mini-probe was placed in direct contact with each polyp and the surrounding mucosa. The endoscopist identified the lateral margins of neoplastic tissue based on pCLE images, then retracted the probe within the snare sheath to prevent thermal damage. Following electrocautery, the probe was redeployed to the tip of the snare to interrogate resection margins, snaring additional tissue as needed. Following removal, the endoscopic diagnosis was compared to the consensus diagnosis of two GI pathologists. **RESULTS:** To date, 3 non-neoplastic and 4 neoplastic polyps (including a small rectal carcinoid tumor) have been removed using our integrated confocal snare. The operator correctly classified the polyp in each case. For two polyps, pCLE assessment of the borders post-resection revealed persistent neoplastic tissue prompting extension of the resection margin. **CONCLUSION:** The integrated confocal snare permits image-guided therapeutic polypectomy. Integration of confocal optics into endoscopic snares is feasible and can guide more complete removal of neoplastic tissue. Classification of polyp types may permit endoscopists to focus efforts on neoplastic polyps, decreasing the morbidity, cost and time of the procedure.

T1222

Small Animal PET-CT as a Non-Invasive Method to Evaluate Terminal Ileal Inflammation in a Murine Model of Crohn's Disease

Pieter Hindryckx, Steven Staelens, Steven Deleje, Harald Peeters, Debby Laukens, Martine De Vos

Background and aims: TNFAARE/+ mice spontaneously develop a chronic terminal ileitis strikingly similar to human Crohn's disease (CD). As such, they represent a unique model to study new therapeutics for intestinal CD. However, animal studies are hampered by inter-animal variability and timing or sampling errors. Small animal molecular imaging may overcome the aforementioned problems. **Aims:** To investigate the use of small animal Positron Emission Tomography (PET) - Computed Tomography (CT) in TNFAARE/+ mice. **Methods:** Methods: TNFAARE/+ mice of several ages and their corresponding healthy control mice were fasted overnight, after which they received an IV injection with 2-Deoxy-2-[18F]Fluoro-D-Glucose and an oral gavage with gastrografin. After one hour, a PET and CT scan of the animals was acquired with the Flex Triumph PET/CT. The resulting images were analyzed and compared with histological inflammation grade. **Results:** The use of gastrografin as an oral contrast agent allowed easy identification of the murine terminal ileum. μ -PET-CT nicely detected terminal ileal inflammation in the TNFAARE/+ mice, with an age-dependent increase in PET-activity and a good correlation with histological inflammation. Virtually no intestinal PET-activity was observed in other parts of the gut in TNFAARE/+ mice or at the terminal ileum in healthy control mice of any age, indicating high specificity of FDG as a PET-tracer for intestinal inflammation. **Conclusion:** Small animal PET-CT is a feasible non-invasive method to evaluate chronic terminal ileal inflammation in TNFAARE/+ mice and may possibly offer a new opportunity to rapidly screen therapeutic compounds for anti-inflammatory activity in Crohn's disease.